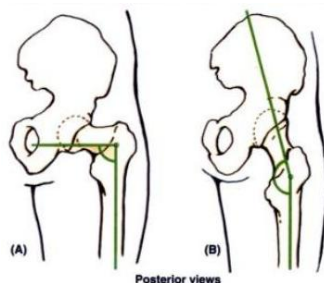


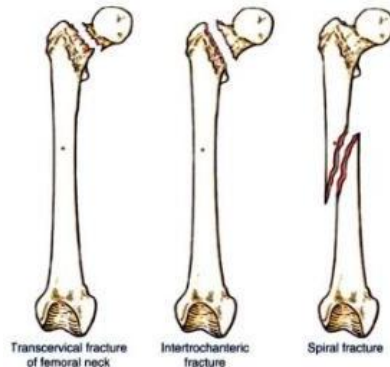
Blue Boxes for Lower Limb

- **Lower Limb Injuries (556)**
 - Knee, leg, and foot injuries are the most common lower limb injuries
 - Injuries to the hip make up <3% of lower limb injuries
 - In general, most injuries result from acute trauma during contact sports such as hockey and football and from overuse during endurance sports such as marathon races
 - Adolescents are most vulnerable to these injuries bc of the demands of sports on their slowly maturing musculoskeletal systems
 - The cartilaginous models of the bones in the developing lower limb are transformed into bone by endochondrial ossification
 - Bc this process is not completed until early adulthood, cartilaginous epiphysal plates still exist during the teenage years when physical activity often peaks and involvement in competitive sports is most common
 - During growth spurts, bones actually grow faster than the attached muscle
 - The combined stress on the epiphysal plates resulting from physical activity and rapid growth may result in irritation and injury of the plates and developing bone (**osteochondrosis**)
- **Injuries of the Hip Bone (Pelvic Injuries) (563)**
 - Fractures of the hip bone are commonly referred to as **pelvic fractures**
 - The term **hip fracture** is commonly applied (unfortunately) to fractures of the femoral head, neck, or trochanters
 - **Avulsion fractures** of the hip bone may occur during sports that require sudden acceleration or deceleration forces
 - Such as sprinting or kicking in football, hurdle jumping, basketball, and martial arts
 - A small part of bone with a piece of tendon or ligament attached is “avulsed” torn away
 - These fractures occur at **apophyses** (bony projections that lack secondary ossification centers)
 - They occur where muscles are attached –
 - Anterior superior and inferior iliac spines, ischial tuberosities, and ischiopubic rami
- **Coxa Vara and Coxa Valga (565)**
 - The angle of inclination between the long axis of the femoral neck and femoral shaft varies with age, sex, and development of the femur (eg a congenital defect in the ossification of the femoral neck)
 - It may also change with any pathological process that weakens the neck of the femur (eg rickets)
 - When the angle is decreased, the condition is **coxa vara (A)**
 - This causes a mild shortening of the lower limb and limits passive abduction of the hip
 - When the angle is increased, the condition is **coxa valga (B)**



- **Dislocated (“Slipped”) Epiphysis of the Femoral Head (565-566)**
 - In older children and adolescents (10-17 yo), the epiphysis of the femoral head may slip away from the femoral neck bc of a weakened epiphysal plate
 - This injury may be caused by acute trauma or repetitive microtraumas that place increased shearing stress on the epiphysis, especially with abduction and lateral rotation of the thigh
 - The epiphysis often dislocates (slips) slowly and regresses in a progressive **coxa vara**
 - The common initial symptom of the injury is hip discomfort that may be referred to the knee
 - Radiographic examination of the superior end of the femur is usually required to confirm a diagnosis of a dislocated epiphysis of the head of the femur
- **Femoral Fractures (566)**
 - Despite its large size and strength, the femur is commonly fractured
 - The type of fracture sustained is frequently age- and even sex-related

- The **neck of the femur** is most frequently fractured bc it is the narrowest and weakest part of the bone and it lies at a marked angle to the line of weight bearing (pull of gravity)
 - It becomes increasingly vulnerable with age, especially in females, secondary to osteoporosis
- Fractures of the **proximal femur** occur at several locations
 - Two examples are **transcervical** (middle of the neck) and **intertrochanteric**
 - These fractures usually occur as a result of indirect trauma (stumbling or stepping down hard, as off a curb or step)
 - Bc of the angle of inclination, these fractures are inherently unstable and impaction (overriding of the fragments resulting in foreshortening of the limb) occurs
 - Muscle spasm also contributes to the shortening of the limb
- **Intracapsular fractures**, occurring within the hip joint capsule, are complicated by degeneration of the femoral head owing to vascular trauma
- Fracture of the **greater trochanter** and **femoral shaft** usually result from direct trauma (direct blows sustained by the bone resulting from falls or being hit) and are most common during the more active years
 - They frequently occur during motor vehicle accidents and sports such as skiing and climbing
 - In some cases a **spiral fracture** of the femoral shaft occurs, resulting in foreshortening as the fragments override, or the fracture may be **comminuted** (broken into several pieces), with the fragments displaced in various directions as a result of muscle pull and depending on the level of the fracture
 - Union of this serious type of fracture may take up to a year
- Fractures of the **distal femur** may be complicated by separation of the condyles
 - This may result in misalignment of the articular surfaces of the knee joint or by hemorrhage from the large popliteal artery that runs directly on the surface of the bone
 - This compromises the blood supply to the leg – an occurrence that should always be considered in knee fractures-dislocations

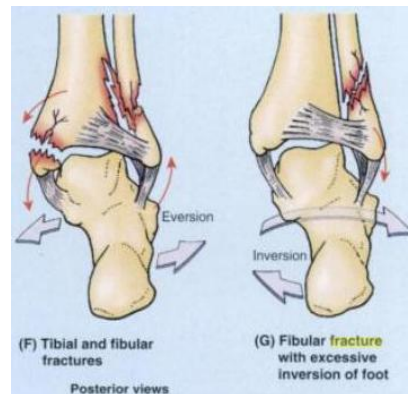


- **Tibial Fractures (568)**

- The tibial shaft is narrowest at the junction of its middle and inferior 1/3s, which is the most frequent site of fracture
 - Unfortunately, this area of the bone also has the poorest blood supply
 - Bc its anterior surface is subcutaneous, the tibial shaft is the most common site for a **compound fracture**
 - Compound tibial fractures may also result from direct trauma (eg a “bumper fracture” caused when a car bumper strikes the leg)
 - Fractures of the tibia through the nutrient canal predisposes the patient to non-union of the bone fragments resulting from damage to the nutrient artery
- **Transverse stress (march) fractures** of the inferior 1/3 of the tibia are common in people who take long hikes before they are conditioned for this activity
 - The strain may fracture the anterior cortex of the tibia
 - Indirect violence applied to the tibial shaft when the bone turns with the foot fixed during a fall may produce a fracture (eg when a person is tackled in football)
- Severe torsion during skiing may produce a **diagonal fracture** of the tibial shaft at the junction of the middle and inferior 1/3s as well as a **fracture of the fibula**
 - Diagonal fractures are often associated with limb shortening caused by overriding at the fractured ends
- Frequently during skiing, a fracture results from a high-speed forward fall, which angles the leg over the rigid ski boot, producing a “**boot-top fracture**”

Lower Limb – Jessica Magid

- Bc of its extensive subcutaneous location, the anterior tibia is accessible for obtaining piece of bone for grafting in children
 - It is also used as a site for intramedullary infusion in dehydrated/shocked children
- **Fractures involving the Epiphyseal Plates (568)**
 - The primary ossification center for the superior end of the tibia appears shortly after birth and joins the shaft of the tibia during adolescence (usually 16-18 yo)
 - Tibial fractures in children are more serious if they involve the epiphysial plates bc continued normal growth of the bone may be jeopardized
 - The tibial tuberosity usually forms by inferior bone growth from the superior epiphysial center at approx 10 yo, but a separate center for the tibial tuberosity may appear at approx 12 yo
 - Disruption of the epiphysial plate at the tibial tuberosity may cause inflammation of the tuberosity and chronic recurring pain during adolescence, especially in young athletes = **Osgood-Schlatter disease**
- **Fibular Fractures (569)**
 - Commonly occur 2-6 cm proximal to the distal end of the lateral malleolus and are often associated with **fracture-dislocations of the ankle joint**, which are combined with tibial fractures (F)
 - When a person slips and the foot is forced into an excessively inverted position, the ankle ligaments tear, forcibly tilting the talus against the lateral malleolus and shearing it off (G)
 - **Fractures of the lateral and medial malleoli** are relatively common in soccer and basketball players
 - Fibular fractures can be painful owing to disrupted muscle attachments
 - Walking is compromised bc of the bone's role in ankle stability



- **Bone Grafts (570)**
 - If part of a major bone is destroyed by injury or disease, the limb becomes useless
 - Replacement of the affected segment by a bone transplant may avoid amputation
 - The fibula is a common source of bone for grafting
 - Even after a segment of shaft has been removed, walking, running, and jumping can be normal
 - Free vascularized fibulas have been used to restore skeletal integrity to upper and lower limbs in which congenital bone defects exist and to replace segments of bone after trauma or excision of a malignant tumor
 - The remaining parts of the fibula usually do not regenerate bc the periosteum and nutrient artery are generally removed with the piece of bone so that the graft will remain alive and grow when transplanted to another site
 - Secured in its new site, the fibular segment restores the blood supply of the bone to which it is now attached
 - Healing proceeds as if a fracture had occurred at each of its ends
 - Awareness of the location of the nutrient foramen in the fibula is important when performing free vascularized fibular transfers
 - Bc the nutrient foramen is located in the middle 1/3 of the fibula in most cases, this segment of the bone is used for transplanting when the graft must include a blood supply to the marrow cavity as well as to the compact bone of the surface (via the periosteum)
- **Calcaneal Fractures (576)**
 - A hard fall onto the heel, from a ladder for ex, may fracture the calcaneus into several pieces, producing a **comminuted fracture**

Lower Limb – Jessica Magid

- A calcaneal fracture is usually disabling bc it disrupts the subtalar (talocalcaneal) joint, where the talus articulates with the calcaneus
- **Fractures of the Talar Neck (576)**
 - Fractures of the talar neck may occur during severe dorsiflexion of the ankle (eg when a person is pressing extremely hard on the brake pedal of a vehicle during a head-on collision)
 - In some cases, the body of the talus dislocates posteriorly
- **Fractures of the Metatarsals (576-577)**
 - Occur when a heavy object falls on the foot, for ex, or when it is run over by a heavy object such as a metal wheel
 - Also common in dancers, especially female ballet dancers who use the demi-pointe technique
 - The **dancer's fracture** usually occurs when the dancer loses balance, putting the full body weight on the metatarsal and fracturing the bone
 - **Fatigue of the metatarsals** may result from prolonged walking
 - These fractures, usually transverse, result from repeated stress on the metatarsals
 - When the foot is suddenly and violently inverted, the tuberosity of the 5th metatarsal may be avulsed by the tendon of the fibularis brevis muscle
 - **Avulsion fractures of the 5th metatarsal tuberosity** are common in basketball and tennis players
 - Part of the tuberosity is pulled off, producing pain and edema at the base of the 5th metatarsal
- **Os Trigonum (577)**
 - During ossification of the talus, the secondary ossification center, which becomes the lateral tubercle of the talus, occasionally fails to unite with the body of the talus
 - This failure may be caused by applied stress (forceful plantarflexion) during the early teens
 - Occasionally, a partly or even fully ossified center may fracture and progress to non-union
 - Either event may result in a bone (accessory ossicle) known as an **os trigonum**, which occurs in 14-25% of adults, more common bilaterally
 - It has an increased prevalence among soccer players and ballet dancers
 - Patients with an os trigonum may be symptomatic or pain free
 - Radionuclide bone scanning, which provides physiological as well as anatomical evidence, is useful in distinguishing symptomatic and asymptomatic ossicles
- **Fracture of the Sesamoid Bones (578)**
 - The sesamoid bones of the great toe in the tendon of the flexor hallucis longus bear the weight of the body, especially during the latter part of the stance phase of walking
 - The sesamoids develop before birth and begin to ossify during late childhood
 - Fracture may result from a crushing injury (eg when a heavy object falls on the great toe)
- **Varicose Veins, Thrombosis, and Thrombophlebitis (583-584)**
 - Frequently, the great saphenous vein and its tributaries become **varicose** (dilated so that the cusps of their valves do not close)
 - Common in the posteromedial parts of the lower limb and may cause considerable discomfort
 - They form when the valves that usually prevent blood flow from the deep veins through the perforating veins to the superficial veins are incompetent
 - When the valves of the great saphenous vein itself are incompetent, the pull of gravity on the uninterrupted column of blood results in a higher intraluminal pressure, which also exacerbates varicosities
 - As a result, the superficial veins become tortuous and dilated
 - The veins of the lower limb are subject to **venous thrombosis** (blood clotting) after a bone fracture
 - **Venous stasis** (stagnation) is an important cause of thrombus formation... it can be caused by –
 - Incompetent, loose fascia that fails to resist muscle expansion, diminishing the effectiveness of the musculovenous pump
 - External pressure on the veins from bedding during a prolonged hospital stay or from a tight cast or bandage
 - Muscular inactivity (eg during an overseas flight)
 - Venous inflammation with thrombus formation (**thrombophlebitis**) may develop around the vein
 - A thrombus that breaks free from a lower limb vein and travels to the lungs constitutes a **pulmonary thromboembolism** (obstruction of a pulmonary artery)
 - A large embolus may obstruct a main pulmonary artery and cause death
- **Saphenous Vein Grafts (584)**

Lower Limb – Jessica Magid

- The great saphenous vein is commonly used for coronary artery bypass bc
 - 1 – it is readily accessible
 - 2 – sufficient distance occurs between the tributaries and the perforating veins so that usable lengths can be harvested
 - 3 – its wall contains a higher percentage of muscular and elastic fibers than do other superficial veins
- Saphenous vein grafts are used to bypass obstructions in blood vessels (eg in an intracoronary thrombus)
 - When part of the great saphenous vein is removed for a bypass, the vein is reversed so that the valves do not obstruct blood flow in the graft
 - Bc there are so many other leg veins, removal of the great saphenous vein rarely produces a significant problem in the lower limb or seriously affects circulation, provided the deep veins are intact
 - In fact, removal of this vein may facilitate the superficial to deep drainage pattern to take advantage of the musculovenous pump
- **Saphenous Cutdown and Saphenous Nerve Injury (584)**
 - Even when it is not visible in infants, in obese people, or in patients in shock whose veins are collapsed, the great saphenous vein can always be located by making a skin incision anterior to the medial malleolus
 - This procedure, called a **saphenous cutdown**, is used to insert a cannula for prolonged administration of blood, plasma expanders, electrolytes, or drugs
 - The saphenous nerve accompanies the great saphenous vein anterior to the medial malleolus
 - Should this nerve be cut during a saphenous cutdown or caught by a ligature during closure of a surgical wound, the patient may complain of pain or numbness along the medial border of the foot
- **Enlarged Inguinal Lymph Nodes (584-585)**
 - Lymph nodes enlarge when diseased
 - **Abrasions** and **minor sepsis**, caused by pathogenic microorganisms or their toxins in the blood or other tissues, may produce slight enlargement of the superficial inguinal lymph nodes (**lymphadenopathy**) in otherwise healthy people
 - Bc these enlarged nodes are located in the subcutaneous tissue, they are easy to palpate in healthy people
 - Those who are unaware of this may be concerned when they feel these nodes bc they assume they have a serious genital disease, for ex
 - When inguinal lymph nodes are enlarged, their entire field of drainage – the trunk inferior to the umbilicus, including the perineum, as well as the entire lower limb – should be examined to determine the cause of their enlargement
 - In female patients, the possibility of metastasis of cancer from the uterus should also be considered
 - Some lymphatic drainage from the uterine fundus may flow along lymphatics accompanying the round ligament of the uterus through the inguinal canal to the superficial inguinal lymph nodes
- **Regional Anesthetic Nerve Blocks of the Lower Limbs (587)**
 - The **iliohypogastric** and **ilioinguinal nerves** can be blocked by injecting an anesthetic agent 4-6cm posterior to the ASIS, along the lateral aspect of the external lip of the iliac crest
 - This is where these nerves perforate the transverse abdominal muscle
 - The **femoral nerve** (L2-L4) can be blocked 2 cm inferior to the inguinal ligament, approx a finger's breadth lateral to the femoral artery
 - Paresthesia (tingling, burning, tickling) radiates to the knee and over the medial side of the leg if the saphenous nerve (terminal branch of the femoral) is affected
- **Variations of the Cutaneous Nerves (588)**
 - They are common
 - For ex, the iliohypogastric and ilioinguinal nerves -
 - May arise from a common trunk of variable length
 - The ilioinguinal nerve may join the iliohypogastric nerve at the iliac crest
 - In this case, the iliohypogastric supplies the cutaneous branches for both nerves
 - When the obturator nerve has a large cutaneous branch, the medial anterior cutaneous branches of the femoral nerve are correspondingly small
- **Abnormalities of Sensory Function (588)**
 - In most instances, a peripheral nerve sensitizing an area of skin represents more than one segment of the spinal cord

Lower Limb – Jessica Magid

- Therefore, to interpret abnormalities of peripheral sensory function, peripheral nerve distribution of the major cutaneous nerves must be interpreted as anatomically different from dermatome distribution of the spinal cord segments
 - Neighboring dermatomes may overlap
- Pain sensation is tested by using a sharp object and asking the patient if pain is felt
 - If there is no sensation, the spinal cord segment(s) involved can be determined
- **Absence of Plantarflexion in Walking (589)**
 - If the muscles of the calf are paralyzed or the calcaneal tendon is ruptured, a much less effective and efficient push off (from the midfoot) can still be accomplished
 - Requires the actions of the gluteus maximus and hamstrings in extending the thigh at the hip joint and the quadriceps in extending the knee
 - Bc push off from the forefoot is not possible (in fact, the ankle will be passively dorsiflexed as the body's weight moves anterior to the foot), those attempting to walk in the absence of plantarflexion often rotate the foot as far laterally (externally) as possible during the stance phase
 - This disables passive dorsiflexion and allows a more effective push off through hip and knee extension exerted at the midfoot
- **Hip and Thigh Contusions (596)**
 - **Contusions** cause bleeding from ruptured capillaries and infiltration of blood into the muscles, tendons, and other soft tissues
 - Sports broadcasters and trainers refer to a “hip pointer,” which is a **contusion of the iliac crest** that usually occurs at its anterior part (eg where the sartorius attaches to the ASIS)
 - This is one of the most common injuries to the hip region, usually occurring in association with collision sports, such as the various forms of football, ice hockey, and volleyball
 - The term “hip pointer” may also refer to avulsion of bony muscle attachments, for ex, of the Sartorius or rectus femoris to the anterior iliac spines, of the hamstrings from the ischium, or of the iliopsoas from the lesser trochanter of the femur
 - However, these injuries should be called **avulsion fractures**
 - Another term commonly used is “charley horse,” which may refer either to the cramping of an individual thigh muscle bc of ischemia or to contusion and rupture of blood vessels sufficient enough to form a hematoma
 - The injury is usually the consequence of tearing of fibers of the rectus femoris
 - Sometimes the quadriceps tendon is partially torn
 - The most common site of a thigh hematoma is in the quadriceps
 - A charley horse is associated with localized pain and/or muscle stiffness and commonly follows direct trauma (eg a stick slash in hockey or a tackle in football)
- **Psoas Abscess (596)**
 - The psoas major arises in the abdomen from the intervertebral discs, the sides of the T12-L5 vertebra, and their transverse processes
 - The medial arcuate ligament of the diaphragm arches obliquely over the proximal part of the psoas major
 - The transversalis fascia on the internal abdominal wall is continuous with the psoas fascia, where it forms a fascial covering for the psoas major that accompanies the muscle into the anterior region of the thigh
 - There is a resurgence of tuberculosis (TB) in Africa, Asia, and elsewhere
 - A retroperitoneal **pyogenic** (pus-forming) infection in the abdomen or greater pelvis, characteristically occurring in association with TB of the vertebral column, or secondary to regional enteritis of the ileum (Crohn disease), may result in the formation of a **psoas abscess**
 - When the abscess passes between the psoas and its fascia to the inguinal and proximal thigh regions, severe pain may be referred to the hip, thigh, or knee joint
 - Consequently, a psoas abscess should always be considered when edema occurs in the proximal part of the thigh
 - Such an abscess may be palpated or observed in the inguinal region, just inferior or superior to the inguinal ligament
 - It may be mistaken for an indirect inguinal hernia or a femoral hernia, an enlargement of the inguinal lymph nodes, or a saphenous varix
 - The lateral border of the psoas is commonly visible in radiographs of the abdomen
 - An obscured psoas shadow may be an indication of abdominal pathology

Lower Limb – Jessica Magid

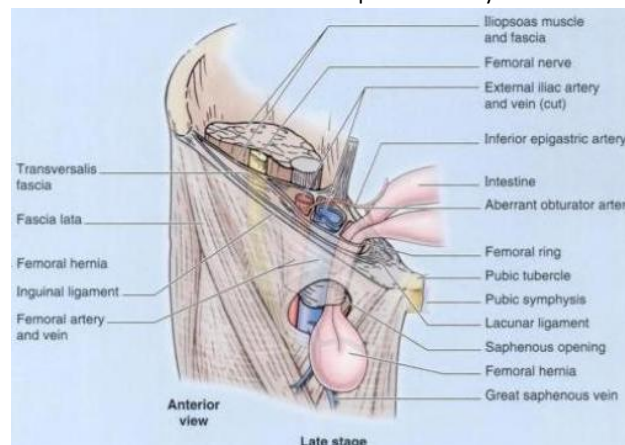
- **Paralysis of the Quadriceps (596)**
 - A person with a paralyzed quadriceps cannot extend the leg against resistance and usually presses on the distal end of the thigh during walking to prevent inadvertent flexion of the knee joint
 - Weakness of the vastus medialis or vastus lateralis, resulting from arthritis or trauma to the knee joint, for ex, can result in abnormal patellar movement and loss of joint stability
- **Chondromalacia Patellae (596)**
 - Also known as **runner's knee**
 - It is a common knee problem for marathon runners
 - Such overstretching of the knee can also occur in running sports such as basketball
 - The soreness and aching around or deep to the patella results from **quadriceps imbalance**
 - It may result from a blow to the patella or extreme flexion of the knee (eg during squatting when power lifting)
- **Patellar Fractures (596-597)**
 - A direct blow to the patella may fracture it in 2 or more fragments
 - **Transverse patellar fractures** may result from a blow to the knee or sudden contraction of the quadriceps (eg when one slips and attempts to prevent a backward fall)
 - The proximal fragment is pulled superiorly with the quadriceps tendon, and the distal fragment remains with the patellar ligament
- **Abnormal Ossification of the Patella (597)**
 - The patella is cartilaginous at birth
 - It becomes ossified during the 3rd-6th years, frequently from more than one ossification center
 - Although these centers usually coalesce and form a single bone, they may remain separate on one or both sides, giving rise to a bipartite or tripartite patella
 - An unwary observer might interpret this condition on a radiograph or CT as a patellar fracture
 - Ossification abnormalities are nearly always bilateral
 - Therefore, diagnostic images should be examined from both sides
 - If the defects are bilateral, the abnormalities are likely ossification abnormalities
- **Patellar Tendon Reflex (597)**
 - Tapping the patellar ligament with a reflex hammer normally elicits the **patellar reflex** (knee jerk)
 - This myotatic (deep tendon) reflex is routinely tested during a physical exam by having a person sit with legs dangling
 - A firm strike on the ligament with a reflex hammer usually causes the leg to extend
 - If the reflex is normal, a hand on the person's quadriceps should feel the muscle contract
 - This tendon tests the integrity of the femoral nerve and the L2-L4 spinal cord segments
 - Tapping the ligament activates muscle spindles in the quadriceps
 - **Afferent impulses** from the spindles travel in the femoral nerve to the L2-L4 segments of the spinal cord
 - From here, **efferent impulses** are transmitted via motor fibers in the femoral nerve to the quadriceps, resulting in a jerk-like contraction of the muscle and extension of the leg at the knee
 - Diminution or absence of the patellar tendon reflex may result from any lesion that interrupts the innervation of the quadriceps (eg peripheral nerve disease)
- **Transplantation of the Gracilis (600)**
 - Bc the gracilis is a relatively weak member of the adductor group of muscles
 - It can be removed without noticeable loss of its actions on the leg
 - Hence, surgeons often transplant the gracilis, or part of it, with its nerve and blood vessels to replace a damaged muscle in the hand, for ex
 - Once the muscle is transplanted, it soon produces good digital flexion and extension
 - Freed from its distal attachment, the muscle has also been relocated and repositioned to create a replacement for a non-functional external anal sphincter
- **Groin Pull (600)**
 - Sports broadcasters refer to a "pulled groin" or "groin injury"
 - These terms mean that a strain, stretching, and probably some tearing of the proximal attachments of the anteromedial thigh muscles has occurred
 - The injury usually involves the flexor and adductor thigh muscles
 - Proximal attachments of these muscles are in the inguinal region (groin), the junction of the thigh and trunk

Lower Limb – Jessica Magid

- Groin pulls usually occur in sports that require quick starts such as short-distance racing (eg a 60m sprint), base stealing in baseball, and quick starts in basketball
- **Injury to the Adductor Longus (600)**
 - **Muscle strains of the adductor longus** may occur in horseback riders and produce pain (rider's strain)
 - Ossification sometimes occurs in the tendons of these muscles bc the horseback riders actively adduct their thighs to keep from falling from their animals
 - The areas of the ossified tendons are sometimes called "riders' bones"
- **Palpation, Compression, and Cannulation of the Femoral Artery (603-604)**
 - The initial part of the femoral artery, proximal to the branching of the deep artery of the thigh, is superficial in position
 - This makes it especially accessible and useful for a number of clinical procedures
 - Some vascular surgeons refer to this part of the femoral artery as the **common femoral artery** and to its continuation distally as the **superficial femoral artery** – not recommended terminology
 - Anterior to the initial part of the femoral artery are the skin, subcutaneous tissue, superficial inguinal lymph nodes, superficial circumflex iliac artery, cribriform fascia, and the anterior part of the femoral sheath
 - With the person lying in the supine position, the **femoral pulse** is palpated midway between the ASIS and the pubic symphysis
 - By placing the tip of the little finger (of the R hand when dealing with the R side) on the ASIS and the tip of the thumb on the pubic tubercle, the femoral pulse can be palpated with the midpalm just inferior to the midpoint of the inguinal ligament by pressing firmly
 - Normally the pulse is strong
 - However, if the common or external iliac arteries are partially occluded, the pulse may be diminished
 - **Compression of the femoral artery** may also be accomplished at this site by pressing directly posteriorly against the superior pubic ramus, psoas major, and femoral head
 - Compression at this point will reduce blood flow through the femoral artery and its branches, such as the deep artery of the thigh
 - The femoral artery can be **cannulated** just inferior to the midpoint of the inguinal ligament
 - In **left cardiac (cardiac) angiography**, a long, slender catheter is inserted into the artery and passed up the external iliac artery, common iliac artery, and aorta to the LV of the heart
 - This same approach via the femoral artery may be used to visualize the coronary arteries in **coronary arteriography**
- **Laceration of the Femoral Artery (604)**
 - The superficial position of the femoral artery in the femoral triangle also makes it vulnerable to traumatic injury, especially laceration
 - Commonly, both the femoral artery and vein are lacerated in anterior thigh wounds bc they lie close together
 - In some cases, an arteriovenous shunt occurs as a result of communication between the injured vessels
 - When it is necessary to ligate the femoral artery, anastomosis of branches of the femoral artery with other arteries that cross the hip joint, may supply blood to the lower limb
 - However, the **cruciate anastomosis**, consisting of a 4-way common meeting of the medial and lateral circumflex femoral arteries with the inferior gluteal artery superiorly and the first perforating artery inferiorly posterior to the femur, occur less commonly than its frequent description in textbooks and depiction in atlases implies
- **Replaced or Accessory Obturator Artery (604)**
 - An enlarged pubic branch of the inferior epigastric artery either takes the place of the obturator artery (**replaced obturator artery**) or joins it as an **accessory obturator artery** in approximately 20% of people
 - This artery runs close to or across the femoral ring to reach the obturator foramen and would be closely related to the neck of a femoral hernia
 - Consequently, this artery could be involved in a **strangulated femoral hernia**
 - Surgeons placing staples during endoscopic repair of both inguinal and femoral hernias must also be vigilant concerning the possible presence of this common arterial variant
- **Potentially Lethal Misnomer (606)**
 - Clinical staff, some vascular laboratories, and even some text and reference books use the term "superficial femoral vein" when referring to the femoral vein before it is joined by the accompanying veins of the deep artery of the thigh (deep femoral veins)
 - Some primary physicians may not have been taught and/or may not realize that the so-called superficial femoral vein is actually a deep vein and that acute thrombosis of this vessel is potentially life threatening
 - The adjective superficial should not be used bc it implies that this vein is a superficial vein
 - Most pulmonary emboli originate in deep veins, not in superficial veins

Lower Limb – Jessica Magid

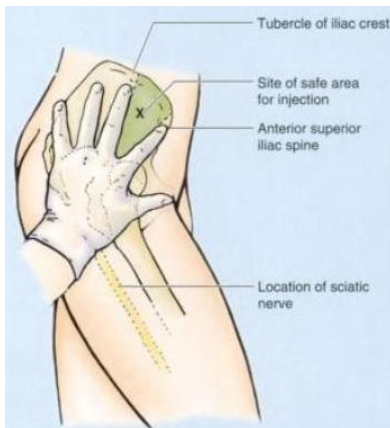- The risk of embolism can be greatly reduced by an anticoagulant treatment
- The use of imprecise language here creates the possibility that an acute thrombosis of this truly deep vessel could be overlooked as an acute clinical issue, and a life-threatening situation created
- Anatomical terminology used in clinical reports must be accurate to avoid possible life-threatening situations
- **Saphenous Varix (606)**
 - A localized dilation of the terminal part of the great saphenous vein – **saphenous varix** – may cause edema in the femoral triangle
 - May be confused with other groin swellings, such as a psoas abscess
 - However, a varix should be considered when varicose veins are present in other parts of the lower limb
- **Location of the Femoral Vein (606)**
 - The femoral vein is not usually palpable but its position can be located inferior to the inguinal ligament by feeling the pulsations of the femoral artery, which is immediately lateral to the vein
 - In thin people, the femoral vein may be close to the surface and may be mistaken for the great saphenous vein
 - It is important therefore to know that the femoral vein has no tributaries at this level, except for the great saphenous vein that joins it approximately 3cm inferior to the inguinal ligament
 - In **varicose vein operations**, it is obviously important to identify the great saphenous vein correctly and not tie off the femoral vein by mistake
- **Cannulation of the Femoral Vein (606)**
 - To secure blood samples and take pressure recordings from the chambers of the R side of the heart and/or from the pulmonary artery and to perform **R cardiac angiography**, a long, slender catheter is inserted into the femoral vein as it passes through the femoral triangle
 - Under fluoroscopic control, the catheter is passed superiorly through the external and common iliac veins into the IVC and RA of the heart
 - Femoral vein puncture may also be used for the administration of fluids
- **Femoral Hernia (607)**
 - The femoral ring is a weak area in the anterior abdominal wall that normally is of a size sufficient to admit the tip of the little finger
 - It is the usual originating site of a **femoral hernia**, a protrusion of abdominal viscera (often a loop of small intestine) through the femoral ring into the femoral canal
 - Appears as a mass, often tender, in the femoral triangle, inferolateral to the pubic tubercle
 - Bounded by the femoral vein laterally and the lacunar ligament medially
 - The hernial sac compresses the contents of the femoral canal (loose connective tissue, fat, and lymphatics) and distends the wall of the canal
 - Initially, the hernia is small bc it is contained within the canal, but it can enlarge by passing inferiorly through the saphenous opening into the subcutaneous tissue of the thigh
 - Femoral hernias are more common in females
 - **Strangulation of a femoral hernia** may occur bc of the sharp, rigid boundaries of the femoral ring, particularly the concave margin of the lacunar ligament
 - Interferes with the blood supply to the herniated intestine
 - This vascular impairment may result in death of the tissues



Lower Limb – Jessica Magid

- **Ischial Bursitis (616)**
 - Recurrent microtrauma resulting from repeated stress (eg as from cycling, rowing, or other activities involving repetitive hip extension while seated, may overwhelm the ischial bursa's ability to dissipate applied stress
 - Results in inflammation of the bursa (**ischial bursitis**)
 - It is a friction bursitis resulting from excessive friction between the ischial bursae and the ischial tuberosities
 - Localized pain occurs over the bursa, and the pain increases with movement of the gluteus maximus
 - Calcification may occur in the bursa with chronic bursitis
 - Bc the ischial tuberosities bear the body weight during sitting, these pressure points may lead to pressure sores in debilitated people, particularly paraplegic persons with poor nursing care
- **Trochanteric Bursitis (616)**
 - Inflammation of the trochanteric bursae, or **trochanteric bursitis**, may result from repetitive actions such as climbing stairs while carrying heavy objects or running on a steeply elevated treadmill
 - These movements involve the gluteus maximus and move the superior tendinous fibers repeatedly back and forth over the bursae of the greater trochanter
 - Causes deep diffuse pain in the lateral thigh region
 - This type of friction bursitis is characterized by point tenderness over the greater trochanter
 - However, the pain radiates along the iliotibial tract that extends from the iliac tubercle to the tibia
 - This thickening of the fascia lata receives tendinous reinforcements from the tensor of the fascia lata and the gluteus maximus
 - The pain from an inflamed trochanteric bursa, usually localized just posterior to the greater trochanter, is generally elicited by manually resisting abduction and lateral rotation of the thigh while the person is lying on the unaffected side
- **Hamstring Injuries (619)**
 - **Hamstring strains** (pulled and/or torn hamstrings) are common in individuals who run and/or kick hard (eg in running, jumping, and quick-start sports such as baseball, basketball, football, and soccer)
 - The violent muscular exertion required to excel in these sports may tear part of the proximal tendinous attachments of the hamstrings to the ischial tuberosity
 - Hamstrings strains are twice as common as quadriceps strains
 - Usually thigh strains are accompanied by contusion and tearing of muscle fibers, resulting in rupture of the blood vessels supplying the muscles
 - The resultant hematoma is contained by the dense stocking-like fascia lata
 - Tearing of hamstring fibers is often so painful when the athlete moves or stretches the leg that he or she falls and writhes in pain
 - These injuries often result from inadequate warming up before practice or competition
 - **Avulsion of the ischial tuberosity** at the proximal attachment of the biceps femoris and semitendinosus ("hurdler's injury") may result from forcible flexion of the hip with the knee extended (eg kicking a football)
- **Injury to the Superior Gluteal Nerve (621-622)**
 - Results in a characteristic motor loss, resulting in disabling **gluteus medius limp**, to compensate for weakened abduction of the thigh by the gluteus medius and minimus, and/or a **gluteal gait**, a compensatory list of the body to the weakened gluteal side
 - This compensation places the center of gravity over the supporting lower limb
 - Medial rotation of the thigh is also severely impaired
 - When a person is asked to stand on one leg, the gluteus medius and minimus normally contract as soon as the contralateral foot leaves the floor, preventing tipping of the pelvis to the unsupported side
 - When a person who has suffered a lesion of the superior gluteal nerve is asked to stand on one leg, the pelvis on the unsupported side descends, indicating that the gluteus medius and minimus on the supported side are weak or non-functional = **positive Trendelenburg test**
 - Other causes of this sign include fracture of the greater trochanter (the distal attachment of the gluteus medius) and dislocation of the hip joint
 - When the pelvis descends on the unsupported side, the lower limb becomes, in effect, too long and does not clear the ground when the foot is brought forward in the swing phase of walking
 - To compensate, the individual leans away from the unsupported side, raising the pelvis to allow adequate room for the foot to clear the ground as it swings forward
 - This results in a characteristic "**waddling**" or **gluteal gait**

- Other ways to compensate is to lift the foot higher as it is brought forward, resulting in the so-called **steppage gait**
- Can also swing the foot outward (laterally) = **swingout gait**
- These same gaits are adopted to compensate for the footdrop that results from common fibular nerve paralysis, which also makes the limb too long
- **Anesthetic Block of the Sciatic Nerve (622-623)**
 - Sensation conveyed by the sciatic nerve can be blocked by the injection of an anesthetic agent a few cm inferior to the midpoint of the line joining the PSIS and the superior border of the greater trochanter
 - Paresthesia radiates to the foot bc of anesthesia of the plantar nerves, which are terminal branches of the tibial nerve derived from the sciatic nerve
- **Injury to the Sciatic Nerve (623)**
 - A pain in the buttock may result from compression of the sciatic nerve by the piriformis muscle = **piriformis syndrome**
 - Individuals involved in sports that require excessive use of the gluteal muscle (eg ice skaters, cyclists, and rock climbers) and women are more likely to develop this syndrome
 - In approx 50% of cases, the case histories indicate trauma to the buttock associated with hypertrophy and spasm of the piriformis
 - In the approx 12% of people in whom the common fibular division of the sciatic nerve passes through the piriformis, this muscle may compress the nerve
 - **Complete section of the sciatic nerve** is uncommon
 - When this occurs, the leg is useless bc extension of the hip is impaired, as is flexion of the leg
 - All ankle and foot movements are also lost
 - **Incomplete section of the sciatic nerve** (eg from stab wounds) may also involve the inferior gluteal and/or the posterior femoral cutaneous nerves
 - Recovery from a sciatic nerve lesion is slow and usually incomplete
 - With respect to the sciatic nerve, the buttock has a side of safety (its lateral side) and a side of danger (its medial side)
 - Wounds or surgery on the medial side of the buttock are liable to injure the sciatic nerve and its branches to the hamstrings (semitendinosus, semimembranosus, and biceps femoris) on the posterior aspect of the thigh
 - Paralysis of these muscles results in impairment of the thigh extension and leg flexion
- **Intragluteal Injections (623-624)**
 - The gluteal region is a common site for intramuscular injection of drugs
 - **Gluteal intramuscular injections** penetrate the skin, fascia, and muscles
 - The gluteal region is a favorable injection site bc the muscles are thick and large
 - So, they provide a substantial volume for absorption of injected substances by intramuscular veins
 - It is important to be aware of the extent of the gluteal region and the safe region for giving injections
 - Some people restrict the area of the buttock to the most prominent part, which may be dangerous bc the sciatic nerve lies deep to this area
 - Injections in the buttock are safe only in the superolateral quadrant of the buttock or superior to a line extending from the PSIS to the superior border of the greater trochanter (approximating the superior border of the gluteus maximus)
 - Intramuscular injections can also be given safely into the anterolateral part of the thigh, where the needle enters the tensor of the fascia lata as it extends distally from the iliac crest and ASIS
 - The index finger is placed on the ASIS, and the fingers are spread posteriorly along the iliac crest until the tubercle of the crest is felt by the middle finger
 - An intragluteal injection can be made safely in the triangular area between the fingers (just anterior to the proximal joint of the middle finger) bc it is superior to the sciatic nerve
 - Complications of improper technique include nerve injury, hematoma, and abscess formation



- **Popliteal Abscesses and Tumors (636)**
 - Bc the deep popliteal fascia is strong and limits expansion, pain from an abscess or tumor in the popliteal fossa is usually severe
 - **Popliteal abscesses** tend to spread superiorly and inferiorly bc of the toughness of the popliteal fascia
 - A popliteal cyst (Baker cyst), a saphenous varix, and an aneurysm of the popliteal artery should be considered in the differential diagnosis of masses within this space
- **Popliteal Pulse (636)**
 - Bc the popliteal artery is deep, it may be difficult to feel the **popliteal pulse**
 - Palpation of this pulse is commonly performed with the person in the prone position with the knee flexed to relax the popliteal fossa and hamstrings
 - The pulsations are best felt in the inferior part of the fossa where the popliteal artery is related to the tibia
 - Weakening or loss of the popliteal pulse is a sign of a femoral artery obstruction
- **Popliteal Aneurysm and Hemorrhage (636)**
 - A **popliteal aneurysm** (abnormal dilation of all or part of the popliteal artery) usually causes edema and pain in the popliteal fossa
 - May be distinguished from other masses by palpable pulsations (**thrills**) and abnormal arterial sounds (**bruits**) detectable with a stethoscope
 - Bc the artery lies deep to the tibial nerve, an aneurysm may stretch the nerve or compress its blood supply (vasa vasorum)
 - Pain from such nerve compression is usually referred, in this case to the skin overlying the medial aspect of the calf, ankle, or foot
 - Bc the artery is closely applied to the popliteal surface of the femur and the joint capsule, fractures of the distal femur or dislocations of the knee may rupture the artery, resulting in hemorrhage
 - Furthermore, bc of their proximity and confinement within the fossa, an injury of the artery and vein may result in an **arteriovenous fistula** (communication between an artery and a vein)
 - Failure to recognize these occurrences and to act promptly may result in the loss of the leg and foot
 - If the femoral artery must be ligated, blood can bypass the occlusion through the genicular anastomosis and reach the popliteal artery distal to the ligation
- **Injury to the Tibial Nerve (636)**
 - Uncommon bc of its deep and protected position in the popliteal fossa
 - However, it may be injured by deep lacerations in the popliteal fossa
 - Posterior dislocation of the knee joint may also damage this nerve
 - Severance of the tibial nerve produces paralysis of the flexor muscles in the leg and the intrinsic muscles in the sole of the foot
 - People with a tibial nerve injury are unable to plantarflex their ankle or flex their toes
 - Loss of sensation also occurs on the sole of the foot
- **Compartment Infection and Syndromes in the Leg (636,638)**
 - The fascial compartments of the limbs are generally closed spaces, ending proximally and distally at the joints
 - Inflammations within the anterior and posterior compartments spread chiefly in a distal direction
 - Suppuration (formation of pus) from purulent (pus-forming) infections in the lateral compartment of the leg, however, can ascend proximally into the popliteal fossa
 - Trauma to muscles and/or vessels in the compartments may produce hemorrhage, edema, and inflammation of the muscles

Lower Limb – Jessica Magid

- Bc the septa and deep fascia of the leg forming the boundaries of the leg compartments are strong, the increased volume consequent to any of these processes increases intracompartmental pressure
 - With arterial bleeding, the pressure may reach levels high enough to compress structures significantly in the compartment(s) concerned
- Structures distal to the compressed area may become ischemic and permanently injured (eg loss of motor function in muscles whose blood supply and/or innervation is affected)
- These conditions, in which increased pressure in a confined space adversely affects the circulation and threatens the function and viability of tissue within or distally, constitute **compartment syndromes**
 - Loss of distal pulses is an obvious sign of arterial compression, as is a lowering of the temperature of tissues distal to the compression
 - A **fasciotomy** (incision of the overlying fascia or a septum) may be performed to relieve the pressure in the compartment(s) concerned
- **Tibialis Anterior Strain (Shin Splints) (642)**
 - Edema and pain in the area of the distal 2/3 of the tibia
 - Result from repetitive microtrauma of the TA, which cause small tears in the periosteum covering the shaft of the tibia and/or of fleshy attachments to the overlying deep fascia of the leg
 - Mild form of the anterior compartment syndrome
 - Commonly occur during traumatic injury or athletic overexertion of muscles in the anterior compartment, especially the TA, by untrained persons
 - Often people who lead sedentary lives develop shin splints when they participate in walk-a-thons (long-distance walks)
 - Also occur in trained runners who do not warm up and cool down sufficiently
 - Muscles in the anterior compartment swell from sudden overuse, and the edema and muscle-tendon inflammation reduce the blood flow to the muscles
 - The swollen muscles are painful and tender to pressure
- **Deep Fibular Nerve Entrapment (642)**
 - Excessive use of muscles supplied by the deep fibular nerve (eg during skiing, running, and dancing) may result in muscle injury and edema in the anterior compartment
 - This entrapment may cause compression of the deep fibular nerve and pain in the anterior compartment
 - Compression of the nerve tight-fitting ski boots, for ex, may occur where the nerve passes deep to the inferior extensor retinaculum and the extensor hallucis brevis
 - Pain occurs in the dorsum of the foot and usually radiates to the web space between the 1st and 2nd toes
 - Bc ski boots are a common cause of this type of nerve entrapment, this condition has been called the “ski boot syndrome”
 - However, it also occurs in soccer players and runners and can result from tight shoes
- **The Fibularis Muscle and Evolution of the Human Foot (645)**
 - Whereas the feet of anthropoids (higher primates) are inverted so that they walk on the outer border of the foot, feet of humans are relatively everted (pronated) so that the soles lie more fully on the ground
 - This pronation is the result, at least in part, to the medial migration of the distal attachment of the fibularis longus across the sole of the foot and the development of a fibularis tertius that is attached to the base of the 5th metatarsal
 - These features are unique to the human foot
- **Injury to the Common Fibular Nerve and Footdrop (646)**
 - Bc of its superficial position, the common fibular is the nerve most injured in the lower limb, mainly bc it winds subcutaneously around the fibular neck, leaving it vulnerable to direct trauma
 - This nerve may also be severed during fracture of the fibular neck or severely stretched when the knee joint is injured or dislocated
 - **Severance of the common fibular nerve** results in flaccid paralysis of all muscles in the anterior and lateral compartments of the leg (dorsiflexors of the ankle and evertors of the foot)
 - The loss of dorsiflexion of the ankle causes **footdrop**, which is further exacerbated by unopposed inversion of the foot
 - This has the effect of making the limb “too long” = the toes do not clear the ground during the swing phase of walking

Lower Limb – Jessica Magid

- There are several other conditions that may result in a lower limb that is “too long” functionally, for ex, pelvic tilt and spastic paralysis or contraction of the soleus
 - There are at least 2 means of compensating for this problem – picture p. 646
 - A **waddling gait**, in which the individual leans to the side opposite the long limb, “hiking” the hip
 - A **swing-out gait**, in which the long limb is swung out laterally (abducted) to allow the toes to clear the ground
 - A high-stepping **steppage gait**, in which extra flexion is employed at the hip and knee to raise the foot as high as necessary to keep the toes from hitting the ground
- Bc the dropped foot makes it difficult to make the heel strike the ground first as in normal gait, a steppage gait is commonly employed in the case of flaccid paralysis
 - Sometimes an extra “kick” is added as the free limb swings forward in an attempt to flip the forefoot upward just before setting the foot down
 - In addition, the braking action normally produced by eccentric contraction of the dorsiflexors is also lost in flaccid paralysis footdrop
 - Therefore, the foot is not lowered to the ground in a controlled manner after heel strike but instead slaps the ground suddenly, producing a distinctive clop and greatly increasing the shock both received by the forefoot and transmitted up the tibia to the knee
- Individuals with a fibular nerve injury may also experience a variable loss of sensation on the anterolateral aspect of the leg and the dorsum of the foot
- **Superficial Fibular Nerve Entrapment (646)**
 - **Chronic ankle sprains** may produce recurrent stretching of the superficial fibular nerve, which may cause pain along the lateral side of the leg and the dorsum of the ankle and foot
 - Numbness and paresthesia (tickling or tingling) may be present and increase with activity
- **Avulsion of the Tuberosity of the 5th Metatarsal (646)**
 - Violent inversion of the foot may cause **avulsion of the tuberosity of the 5th metatarsal**, the distal attachment of the fibularis brevis
 - This avulsion fracture is associated with a severely sprained ankle
 - Injury to the associated superficial fibular nerve causes inversion of the foot bc of paralysis of the fibular muscles in the lateral compartment
- **Fabella in the Gastrocnemius (649)**
 - Close to its proximal attachment, the lateral head of the gastrocnemius contains a sesamoid bone, the **fabella**, which articulates with the lateral femoral condyle and is visible in lateral radiographs of the knee in 3-5% of people
- **Calcaneal Tendinitis (649,652)**
 - Inflammation of the calcaneal tendon constitutes 9-18% of running injuries
 - Microscopic tears of collagen fibers in the tendon, particularly just superior to its attachment to the calcaneus, results in **tendinitis**
 - Causes pain during walking, especially when wearing rigid-soled shoes
 - Often occurs during repetitive activities, especially in individuals who take up running after prolonged inactivity or suddenly increase the intensity of their training, but it may also result from poor footwear or training surfaces
- **Ruptured Calcaneal Tendon (652)**
 - Rupture of the calcaneal tendon is often sustained by poorly conditioned people with a history of calcaneal tendinitis
 - The injury is typically experienced as an audible snap during a forceful push off (plantarflexion with the knee extended) followed immediately by sudden calf pain and sudden dorsiflexion of the plantarflexed foot
 - In a completely ruptured tendon, a gap is palpable, usually 1-5cm proximal to the calcaneal attachment
 - **Calcaneal tendon rupture** is probably the most severe acute muscular problem of the leg
 - People with this injury cannot plantarflex against resistance (cannot raise the heel from the ground or balance on the affected side), and passive dorsiflexion (usually limited to 20° from neutral) is excessive
 - Ambulation is possible only when the limb is externally rotated, rolling over the transversely placed foot during the stance phase without push off
 - Bruising appears in the malleolar region, and a lump usually appears in the calf owing to shortening of the triceps surae

Lower Limb – Jessica Magid

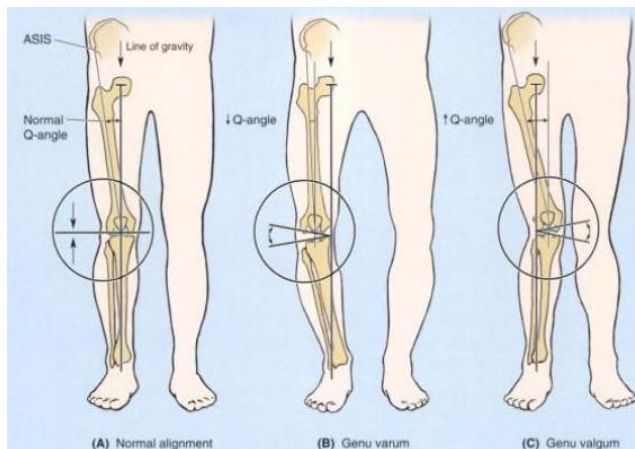
- In older or non-athletic people, non-surgical repairs are often adequate, but surgical intervention is usually advised for those with active lifestyles
- **Calcaneal Tendon Reflex (652)**
 - The ankle (jerk) reflex, the calcaneal tendon reflex, is a myotatic reflex elicited while the person's legs are dangling over the side of the examining table
 - The calcaneal tendon is struck briskly with a reflex hammer just proximal to the calcaneus
 - The normal result is plantarflexion of the ankle joint
 - The calcaneal reflex tests the S1 and S2 nerve roots
 - If the S1 nerve root is injured or compressed, the ankle reflex is virtually absent
- **Gastrocnemius Strain (652)**
 - Also called **tennis leg**
 - Painful acute injury resulting from partial tearing of the medial belly of the gastrocnemius at or near its musculotendinous junction, often seen in individuals older than 40 years of age
 - It is caused by overstretching the muscle by concomitant full extension of the knee and dorsiflexion of ankle joint
 - Usually, an abrupt onset of stabbing pain is followed by edema and spasm of the gastrocnemius
- **Calcaneal Bursitis (652)**
 - Also called **retroachilles bursitis**
 - Results from inflammation of the bursa of the calcaneal tendon located between the calcaneal tendon and the superior part of the posterior surface of the calcaneus
 - Causes pain posterior to the heel and occurs quite commonly during long-distance running, basketball, and tennis
 - It is caused by excessive friction on the bursa as the tendon continuously slides over it
 - Inflammation of the subcutaneous calcaneal bursa also results from repetitive microtrauma from the backs of shoes, usually new ones
- **Venous Return from the Leg (652)**
 - A venous plexus deep to the triceps surae is involved in the return of blood from the leg
 - When a person is standing, the venous return from the leg depends largely on the muscular activity of the triceps surae
 - Contraction of the calf muscles pumps blood superiorly in the deep veins
 - The efficiency of the calf pump is improved by the deep fascia that invests the muscles like an elastic stocking
 - Normally, blood is prevented from flowing into the superficial veins by the valves in the perforating veins
 - If those valves are incompetent, blood is forced into the superficial veins during contraction of the triceps surae and by hydrostatic pressure when straining or standing
 - As a consequence, the vessels become dilated and tortuous varicose veins
- **Accessory Soleus (653)**
 - An accessory soleus is present in approx 3% of people
 - The accessory muscle usually appears as a distal belly medial to the calcaneal tendon
 - Clinically, it may be associated with pain and edema during prolonged exercise
- **Posterior Tibial Pulse (656)**
 - Can usually be palpated between the posterior surface of the medial malleolus and the medial border of the calcaneal tendon
 - Bc the posterior tibial artery passes deep to the flexor retinaculum, it is important when palpating this pulse to have the person invert the foot to relax the retinaculum
 - Failure to do so may lead to the erroneous conclusion that the pulse is absent
 - Both arteries are examined simultaneously for equality of force
 - Palpation of the posterior tibial pulses is essential for examining patients with occlusive peripheral artery disease
 - Although the posterior tibial pulses are absent in approx 15% of normal young people, absence of posterior tibial pulses is considered to be a sign of occlusive peripheral artery disease in people older than 60 years
 - For ex, intermittent claudication, characterized by leg pain and cramps, develops during walking and disappears after rest
 - These conditions result from ischemia of the leg muscles caused by narrowing or occlusion of the leg arteries
- **Plantar Fasciitis (663)**
 - Straining and inflammation of the plantar aponeurosis
 - May result from running and high-impact aerobics, especially when inappropriate footwear is worn
 - Most common hindfoot problem in runners

- Causes pain on the plantar surface of the heel and on the medial aspect of the foot
 - Pain is often most severe after sitting and when beginning to walk in the morning, but dissipates after 5-10min of activity, often recurring again following rest
 - Point tenderness is located at the proximal attachment of the aponeurosis to the medial tubercle of the calcaneus and on the medial surface of this bone
 - Pain increase with passive extension of the great toe and may be further exacerbated by dorsiflexion of the ankle and/or weight bearing
- If a **calcaneal spur** (abnormal bony process) protrudes from the medial tubercle, plantar fasciitis is likely to cause pain on the medial side of the foot when walking
- Usually a bursa develops at the end of the spur that may also become inflamed and tender
- **Infections of the Foot** (666,668)
 - Foot infections are common, especially in seasons, climates, and cultures where shoes are less commonly worn
 - A neglected puncture wound may lead to an extensive deep infection, resulting in swelling, pain, and fever
 - Deep infections of the foot often localize within the compartments between the muscular layers
 - A well-established infection in one of the enclosed fascial or muscular spaces usually requires surgical incision and drainage
 - When possible, the incision is made on the medial side of the foot, passing superior to the abductor hallucis to allow visualization of critical neurovascular structures, while avoiding production of a painful scar in a weight-bearing area
- **Contusion of the Extensor Digitorum Brevis** (668)
 - Functionally, the EDB and EHB muscles are relatively unimportant
 - Clinically, knowing the location of the belly of the EDB is important for distinguishing it from abnormal edema
 - Contusion and tearing of the muscle's fibers and associated blood vessels result in a hematoma, producing edema anteromedial to the lateral malleolus
 - Most people who have not seen this inflamed muscle assume they have a severely sprained ankle
- **Sural Nerve Grafts** (669)
 - Pieces of the sural nerve are often used for nerve grafts in procedures such as repairing nerve defects resulting from wounds
 - The surgeon is usually able to locate this nerve in relation to the small saphenous vein
 - Bc of the variations in the level of formation of the sural nerve, the surgeon may have to make incisions in both legs, and then select the better specimen
- **Anesthetic Block of the Superficial Fibular Nerve** (669)
 - After the superficial fibular nerve pierces the deep fascia to become a cutaneous nerve, it divide into medial and intermediate cutaneous nerves
 - In thin people, these branches can often be seen or felt as ridges under the skin when the foot is plantarflexed
 - Injections of an anesthetic agent around these branches in the ankle region, anterior to the palpable portion of the fibula, anesthetizes the skin on the dorsum of the foot (except the web between the adjacent surfaces of the 1st and 2nd toes)
 - It is more broad and effective than more local injections on the dorsum of the foot for superficial surgery
- **Plantar Reflex** (669)
 - L4-S2 nerve roots
 - A myotatic (deep tendon) reflex that is routinely tested during neurological exams
 - The lateral aspect of the sole of the foot is stroked with a blunt object, such as a tongue depressor, beginning at the heel and crossing to the base of the great toe
 - The motion is firm and continuous but neither painful nor ticklish
 - Flexion of the toes is a normal response
 - Slight fanning of the lateral 4 toes and dorsiflexion of the great toe is an abnormal response = **Babinski sign**
 - Indicates brain injury or cerebral disease, except in infants
 - Bc the corticospinal tracts are not fully developed in newborns, a Babinski sign is usually elicited and may be present until children are 4 yo
- **Medial Plantar Nerve Entrapment** (669)
 - Compression irritation of the medial plantar nerve as it passes deep to the flexor retinaculum or curves deep to the abductor hallucis may cause aching, burning, numbness, and tingling (paresthesia) on the medial side of the sole and in the region of the navicular tuberosity

- **Medial plantar nerve compression** may occur during repetitive eversion of the foot (eg during gymnastics and running)
- Bc of its frequency in runners, these symptoms have been called “jogger’s foot”
- **Palpation of the Dorsalis Pedis Pulse** (670-671)
 - The pulse of the **dorsal artery of the foot** is evaluated during a physical exam of the peripheral vascular system
 - May be palpated with the feet slightly dorsiflexed
 - Usually easy to palpate bc the dorsal arteries of the foot are subcutaneous and pass along a line from the extensor retinaculum to a point just lateral to the EHL tendons
 - A diminished or absent dorsalis pedis usually suggests vascular insufficiency resulting from arterial disease
 - The 5 **P signs of acute arterial occlusion** = pain, pallor, paresthesia, paralysis, and pulselessness
 - Some healthy adults (and even children) have **congenitally non-palpable dorsalis pedis pulses**
 - The variation is usually bilateral
 - In these cases, the dorsal artery of the foot is replaced by an enlarged perforating fibular artery
- **Hemorrhaging Wounds of the Sole of the Foot** (671)
 - Puncture wounds of the sole of the foot involving the deep plantar arch and its branches usually result in severe bleeding, typically from both ends of the cut artery bc of the abundant anastomoses
 - Ligation of the arch is difficult bc of its depth and the structures that surround it
- **Lymphadenopathy** (672)
 - Infections of the foot may spread proximally, causing enlargement of the popliteal and inguinal lymph nodes
 - Infections on the lateral side of the foot initially produce enlargement of the popliteal lymph nodes = **popliteal lymphadenopathy**
 - Later, the inguinal lymph nodes may enlarge
 - **Inguinal lymphadenopathy** without popliteal lymphadenopathy can result from infection of the medial side of the foot, leg, or thigh
 - However, enlargement of these nodes can also result from an infection or tumor in the vulva, penis, scrotum, perineum, and gluteal region and from the terminal parts of the urethra, anal canal, and vagina
- **Bipedalism and Congruity of the Articular Surfaces of the Hip Joint** (675-676)
 - The acetabulum is directed inferiorly, laterally, and anteriorly in humans
 - The weight-bearing iliac portion of the acetabular rim overlies the femoral head, which is important for transfer of weight to the femur in the erect (standing/walking) position
 - Consequently, of the positions commonly assumed by humans, the hip joint is mechanically most stable when a person is bearing weight, as lifting a heavy object, for ex
 - Decreases in the degree to which the ilium overlies the femoral head (detectable radiographically as the **angle of Wiberg**) may indicate joint instability
 - Bc of the anterior direction the axis of the acetabulum and the posterior direction of the axis of the femoral head and neck as it extends laterally (owing to the torsion angle), there is an angle of 30-40° between their axes
 - Consequently, the articular surfaces of the head and acetabulum are not fully congruent in the erect (bipedal) posture
 - The anterior part of the femoral head is “exposed” and articulates mostly with the joint capsule
 - Nonetheless, rarely is <40% of the available articular surface of the femoral head in contact with the surface of the acetabulum in any position
 - Relative to other joints and in view of the large size of the hip joint, this is extensive contact, contributing considerably to the joint’s great stability
- **Fractures of the Femoral Neck (“Hip Fractures”)** (682)
 - **Fractures of the neck of the femur** – unfortunately referred to as “fractured hips,” implying that the hip bone is broken
 - Uncommon in most contact sports bc the participants are usually young and the femoral neck is strong in people <40 years of age
 - When they do occur in this age group, these fractures usually result from high-energy impacts (eg during race-car accidents, skiing, trampoline, and equestrian events) when the lower limb is extended and the force of the impact is transmitted to the hip joint, even if applied at some distance from the joint

- For ex, if the foot is firmly braced against the car floor when the knee is locked, or if the knee is braced against the dashboard during a head-on collision, the force of impact may be transmitted superiorly and produce a femoral neck fracture
 - These fractures are especially common in individuals >60 years, especially in women bc their femoral necks are more often weak and brittle as a result of osteoporosis
 - Fractures are often intracapsular, and realignment of the neck fragments requires internal skeletal fixation
 - They are among the most troublesome and problematic of all fractures
 - Often disrupt the blood supply to the head of the femur
 - Most of the blood to the head and neck of the femur is supplied by the medial circumflex femoral artery
 - The retinacular arteries arising from this artery are often torn when the femoral neck is fractured or the hip joint is dislocated
 - Following some femoral neck fractures, the artery to the ligament of the femoral head may be the only remaining source of blood to the proximal fragment
 - This artery is frequently inadequate for maintaining the femoral head
 - So, the fragment may undergo **aseptic vascular necrosis**
- **Surgical Hip Replacement (682)**
 - Although the hip joint is strong and stable, it is subject to severe traumatic injury and degenerative disease
 - **Osteoarthritis of the hip joint**, characterized by pain, edema, limitation of motion, and erosion of the articular cartilage, is a common cause of disability
 - During hip replacement, a metal prosthesis anchored to the person's femur by bone cement replaces the femoral head and neck
 - A plastic socket cemented to the hip bone replaces the acetabulum
- **Necrosis of the Femoral Head in Children (682-683)**
 - In children, traumatic dislocations of the hip joint disrupt the artery to the head of the femur
 - Fractures that result in separation of the superior femoral epiphysis (the growth plate between the femoral head and neck) are also likely or result in inadequate blood supply to the femoral head and in **post-traumatic avascular necrosis of the head**
 - As a result, incongruity of the joint surfaces develops, and growth at the epiphysis is retarded
 - Such conditions, most common in children age 3-9, produce hip pain that may radiate to the knee
- **Dislocation of the Hip Joint (683)**
 - **Congenital dislocation of the hip joint** is common, occurring in approx 1.5/1000 live births
 - It is bilateral in approx ½ of the cases
 - Girls are affected at least 8x more than boys
 - Dislocation occurs when the femoral head is not properly located in the acetabulum
 - Inability to abduct the thigh is characteristic of congenital dislocation
 - In addition, the affected limb appears (and functions as if) shorter bc the dislocated femoral head is more superior than on the normal side, resulting in a **positive Trendelenburg sign** (hip appears to drop to one side during walking)
 - Approx 25% of all cases of arthritis of the hip in adults are the direct result of residual defects from congenital dislocation
 - **Acquired dislocation of the hip joint** is uncommon bc this articulation is so strong and stable
 - Nevertheless, dislocation may occur during a car accident when the hip is flexed, adducted, and medially rotated, the usual position of the lower limb when a person is riding in a car
 - **Posterior dislocations** are most common
 - A head-on collision that causes the knee to strike the dashboard may dislocate the hip when the femoral head is forced out of the acetabulum
 - The joint capsule ruptures inferiorly and posteriorly, allowing the femoral head to pass through the tear in the capsule and over the posterior margin of the acetabulum onto the lateral surface of the ilium, shortening and medially rotating the affected limb
 - Bc of the close relationship of the sciatic nerve to the hip joint, it may be injured (stretched and/or compressed) during posterior dislocations or fracture-dislocations of the hip joint
 - This kind of injury may result in paralysis of the hamstrings and muscles distal to the knee supplied by the sciatic nerve

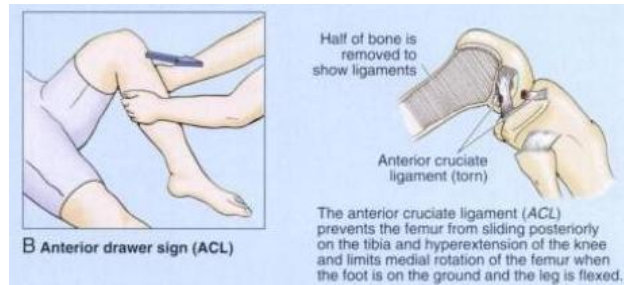
- Sensory changes may also occur in the skin over the posterolateral aspects of the leg and over much of the foot bc of injury to the sensory branches of the sciatic nerve
 - **Anterior dislocation** of the hip joint results from a violent injury that forces the hip into extension, abduction, and lateral rotation (eg catching a ski tip when snow skiing)
 - In these cases, the femoral head is inferior to the acetabulum
 - Often, the acetabular margin fractures, producing a fracture-dislocation of the hip joint
 - When the femoral head dislocates, it usually carries the acetabular bone fragment and acetabular labrum with it
- **Genu Valgum and Genu Varum** (687,689)
 - The femur is placed diagonally within the thigh, whereas the tibia is almost vertical within the leg, creating an angle at the knee between the long axes of the bones
 - The angle between the 2 bones, referred to clinically as the **Q-angle**, is assessed by drawing a line from the ASIS to the middle of the patella and extrapolating a 2nd (vertical) line passing through the middle of the patella and tibial tuberosity
 - The Q-angle is typically greater in adult females, owing to their wider pelvis
 - When normal, the angle of the femur within the thigh places the middle of the knee joint directly inferior to the head of the femur when standing, centering the weight-bearing line in the intercondylar region of the knee
 - A medial angulation of the leg in relation to the thigh, in which the femur is abnormally vertical and the Q-angle is small, is a deformity called **genu varum** (bowleg) that causes unequal weight bearing (B)
 - The line of weight bearing falls medial to the center of the knee
 - Excess pressure is placed on the medial aspect of the knee joint, which results in **arthrosis** (destruction of knee cartilages), and the fibular collateral ligament is overstressed
 - A lateral angulation of the leg (large Q-angle, >17°) in relation to the thigh (exaggeration of the knee angle) is called **genu valgum** (knock-knee) (C)
 - Bc of the exaggerated knee angle, the weight-bearing line falls lateral to the center of the knee
 - Consequently, the tibial collateral ligament is overstretched, and there is excess stress on the lateral meniscus and cartilages of the lateral femoral and tibial condyles
 - The patella, normally pulled laterally by the tendon of the vastus lateralis, is pulled even farther laterally when the leg is extended in the presence of genu valgum so that its articulation with the femur is abnormal
 - Children commonly appear bowlegged for 1-2 years after starting to walk, and knock-knees are frequently observed in children 2-4 yo
 - Persistence of these abnormal knee angles in late childhood usually means congenital deformities exist that may require correction
 - Any irregularity of a joint eventually leads to wear and tear (arthrosis) of the articular cartilages



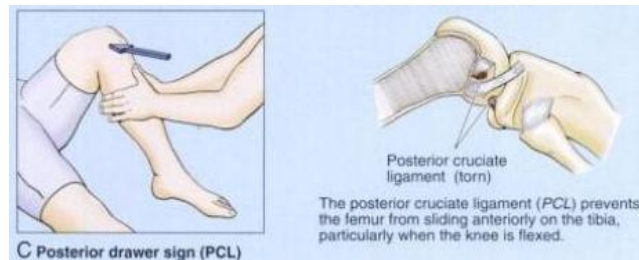
- **Patellar Dislocation** (689-690)
 - When the patella is dislocated, it nearly always dislocates laterally
 - It is more common in women, presumably bc of their greater Q-angle which, in addition to representing the oblique placement of the femur in relative to the tibia, represents the angle of pull of the quadriceps relative to the axis of the patella and tibia

Lower Limb – Jessica Magid

- The term Q-angle was actually coined in reference to the angle of pull of the quadriceps
- The tendency toward lateral dislocation is normally counterbalanced by the medial, more horizontal pull of the powerful vastus medialis
 - In addition, the more anterior projection of the lateral femoral condyle and deeper slope for the larger lateral patellar facet provide a mechanical deterrent to lateral dislocation
 - An imbalance of the lateral pull and the mechanisms resisting it result in abnormal tracking of the patella within the patellar groove and chronic patellar pain, even if actual dislocation does not occur
- **Patellofemoral Syndrome (690)**
 - Pain deep to the patella often results from excessive running, especially downhill
 - Hence, this type of pain is often called “runner’s knee”
 - The pain results from repetitive microtrauma caused by abnormal tracking of the patella relative to the patellar surface of the femur = **patellofemoral syndrome**
 - May also result from a direct blow to the patella and from **osteoarthritis of the patellofemoral compartment** (degenerative wear and tear of articular cartilages)
 - In some cases, strengthening of the vastus medialis corrects patellofemoral dysfunction
 - This muscle tends to prevent laterally dislocation of the patella resulting from the Q-angle bc the vastus medialis attaches to and pulls on the medial border of the patella
 - Hence, weakness of the vastus medialis predisposes the individual to the patellofemoral dysfunction and patellar dislocation
- **Knee Joint Injuries (695,697-699)**
 - Common bc the knee is a low-placed, mobile, weight-bearing joint, serving as a fulcrum between 2 long levers (thigh and leg)
 - It’s stability depends almost entirely on its associated ligaments and surrounding muscles
 - It is essential for everyday activities such as standing, walking, and climbing stairs
 - It is also a main joint for sports that involve running, jumping, kicking, and changing directions
 - To perform these activities, the knee joint must be mobile
 - However, this mobility makes it susceptible to injuries
 - The most common knee injuries in contact sports are **ligament sprains**, which occur when the foot is fixed in the ground
 - If a force is applied against the knee when the foot cannot move, ligament injuries are likely to occur
 - The tibial and fibular collateral ligaments (TCL and FCL) are tightly stretched when the leg is extended, normally preventing disruption of the sides of the knee joint
 - The firm attachment of the TCL to the medial meniscus is of considerable clinical significance bc tearing of this ligament frequently results in concomitant tearing of the medial meniscus
 - The injury is frequently caused by a blow to the lateral side of the extended knee or excessive lateral twisting of the knee that disrupts the TCL and concomitantly tears and/or detaches the medial meniscus from the joint capsule
 - This injury is common in athletes who twist their flexed knees while running (eg in basketball, the various forms of football, and volleyball)
 - The ACL, which serves as a pivot for rotatory movements of the knee and is taut during flexion, may also tear subsequent to the rupture of the TCL, creating an “unhappy triad” of knee injuries
 - Hyperextension and severe force directed anteriorly against the femur with the knee semiflexed (eg a crossbody block in football) may tear the ACL
 - **ACL ruptures** are also common knee injuries in ski accidents
 - This injury causes the free tibia to slide anteriorly under the fixed femur = **anterior drawer sign**
 - The ACL may tear away from the femur or tibia
 - However, tears commonly occur in the midportion of the ligament

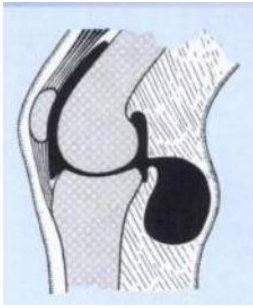


- Although strong, **PCL ruptures** may occur when a player lands on the tibial tuberosity with the knee flexed (eg when knocked to the floor in basketball)
 - PCL ruptures usually occur in conjunction with tibial or fibular ligament tears
 - These injuries can also occur in head-on collisions when seat belts are not worn and the proximal end of the tibia strikes the dashboard
 - Allow the tibia to slide posteriorly under the fixed femur = **posterior drawer sign**



- **Meniscal tears** usually involve the medial meniscus
 - The lateral meniscus does not usually tear bc of its mobility
 - Pain on lateral rotation of the tibia on the femur indicates injury of the lateral meniscus
 - Pain on medial rotation of the tibia on the femur indicates injury of the medial meniscus
 - Most meniscal tears occur in conjunction with TCL or ACL tears
 - Peripheral tears can often be repaired or may heal on their own bc of the generous blood supply to this area
 - Tears that do not heal or cannot be repaired are usually removed (eg by arthroscopic surgery)
 - Knee joints from which the menisci have been removed suffer no loss of mobility
 - However, the knee may be less stable and the tibial plateaus often undergo inflammatory reactions
- **Arthroscopy of the Knee Joint (699)**
 - **Arthroscopy** is an endoscopic exam that allows visualization of the interior of the knee joint cavity with minimal disruption of tissue
 - The arthroscope and one (or more) additional canula(e) are inserted through tiny incisions, known as portals
 - The 2nd canula is for passage of specialized tools (eg manipulative probes or forceps) or equipment for trimming shaping, or removing damaged tissue
 - This technique allows removal of torn menisci, loose bodies in the joint (such as bone chips), and debridement (the excision of devitalized articular cartilaginous material) in advanced cases of arthritis
 - Ligament repair or replacement may also be performed using an arthroscope
 - Although general anesthesia is usually preferable, knee arthroscopy can be performed using local or regional anesthesia
 - During arthroscopy, the articular cavity of the knee must be treated essentially as 2 separate (medial and lateral) femorotibial articulations owing to the imposition of the synovial fold around the cruciate ligaments
- **Aspiration of the Knee Joint (699-700)**
 - Fractures of the distal end of the femur or lacerations of the anterior thigh may involve the suprapatellar bursa and result in infection of the knee joint
 - When the knee joint is infected and inflamed, the amount of synovial fluid may increase

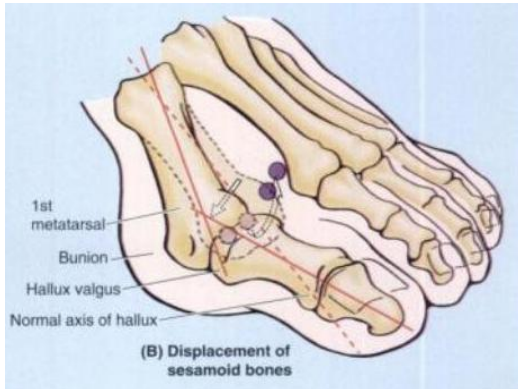
- **Joint effusions**, the escape of fluid from blood or lymphatic vessels, results in increased amounts of fluid in the joint cavity
 - Bc the suprapatellar bursa communicates freely with the synovial cavity of the knee joint, fullness of the thigh in the region of the suprapatellar bursa may indicate increased synovial fluid
 - This bursa can be aspirated to remove the fluid for examination
 - **Direct aspiration** of the knee joint is usually performed with the patient sitting on a table with the knee flexed
 - The joint is approached laterally, using 3 bony points as landmarks for needle insertion –
 - The anterolateral tibial (Gerdy) tubercle
 - The lateral epicondyle of the femur
 - The apex of the patella
 - In addition to being the route for aspiration of serous and sanguineous (bloody) fluid, this triangular area also lends itself to drug injection for treating pathology of the knee
- **Bursitis in the Knee Region (700)**
 - **Prepatellar bursitis** is caused by friction between the skin and the patella
 - However, the bursa may also be injured by compressive forces resulting from a direct blow or from falling on the flexed knee
 - If the inflammation is chronic, the bursa becomes distended with fluid and forms a swelling on the anterior of the knee
 - This condition has been called “housemaid’s knee”
 - However, other people who work on their knees without knee pads, such as hardwood floor and rug installers, may also develop prepatellar bursitis
 - **Subcutaneous infrapatellar bursitis** is caused by excessive friction between the skin and the tibial tuberosity
 - The edema occurs over the proximal end of the tibia
 - This condition was formerly called “clergyman’s knee” bc of frequent genuflexing (genu = knee in Latin)
 - However, it occurs more commonly in roofers and floor tillers if they do not wear knee pads
 - **Deep infrapatellar bursitis** results in edema between the patellar ligament and the tibia, superior to the tibial tuberosity
 - The inflammation is usually caused by overuse and subsequent friction between the patellar tendon and the structures posterior to it
 - Enlargement of the deep infrapatellar bursa obliterates the dimples normally occurring on each side of the patellar ligament when the leg is extended
 - Abrasions or penetrating wounds may result in **suprapatellar bursitis**, an infection caused by bacteria entering the bursa from the torn skin
 - The infection may spread to the cavity of the knee joint, causing localized redness and enlarged popliteal and inguinal lymph nodes
- **Popliteal Cysts (700)**
 - Also known as **Baker cysts**
 - Abnormal fluid-filled sacs of synovial membrane in the region of the popliteal fossa
 - Almost always a complication of chronic knee joint effusion
 - May be a herniation of the gastrocnemius or semimembranosus bursa through the fibrous layer of the joint capsule into the popliteal fossa, communicating with the synovial cavity of the knee joint by a narrow stalk
 - Synovial fluid may also escape from the knee joint (**synovial effusion**) or a bursa around the knee and collect in the popliteal fossa
 - Here it forms a new synovial-liked sac, or popliteal cyst
 - Common in children but seldom cause symptoms
 - In adults, they can be large, extending as far as the midcalf, and may interfere with knee movements



- **Knee Replacement (700-701)**
 - If a person's knee is diseased, resulting from osteoarthritis, for ex, an artificial knee joint may be inserted = **total knee replacement arthroplasty**
 - The artificial knee joint consists of plastic and metal components that are cemented to the femoral and tibial bone ends after removal of the defective areas
 - The combination of metal and plastic mimics the smoothness of cartilage on cartilage and produces good results in "low-demand" people who have a relatively sedentary life
 - In "high-demand" people who are active in sports, the bone-cement junctions may break down, and the artificial components may loosen
 - However, improvements in bioengineering and surgical technique have provided better results
- **Ankle Injuries (706)**
 - The ankle is the most frequently injured major joint in the body
 - **Ankle sprains** (torn fibers of ligaments) are most common
 - A sprained ankle is nearly always an **inversion injury**, involving twisting of the weight-bearing plantarflexed foot
 - The person steps on an uneven surface and the foot is forcibly inverted
 - **Lateral ligament sprains** occur in sports in which running and jumping are common, particularly basketball (70-80% of players have had at least one sprained ankle)
 - The lateral ligament is injured bc it is much weaker than the medial ligament and is the ligament that resists inversion at the talocrural joint
 - The **anterior talofibular ligament** – part of the lateral ligament – is most vulnerable and most commonly torn during ankle sprains, either partially or completely, resulting in instability of the ankle joint
 - The **calcaneofibular ligament** may also be torn
 - In severe sprains, the lateral malleolus of the fibula may be fractured
 - **Shearing injuries** fracture the lateral malleolus at or superior to the ankle joint
 - **Avulsion fractures** break the malleolus inferior to the ankle joint – a fragment of bone is pulled off by the attached ligament(s)
 - A **Pott fracture-dislocation of the ankle** occurs when the foot is forcibly everted
 - This action pulls on the extremely strong medial ligament, often tearing off the medial malleolus
 - The talus then moves laterally, shearing off the lateral malleolus or, more commonly, breaking the fibula superior to the tibiofibular syndesmosis
 - If the tibia is carried anteriorly, the posterior margin of the distal end of the tibia is also sheared off by the talus, producing a "**trimalleolar fracture**"
 - In applying this term to this injury, the entire distal end of the tibia is erroneously considered to be a "malleolus"
 - **Tibial Nerve Entrapment (706-707)**
 - The tibial nerve leaves the posterior compartment of the leg by passing deep to the flexor retinaculum in the interval between the medial malleolus and the calcaneus
 - Entrapment and compression of the tibial nerve (**tarsal tunnel syndrome**) occurs when there is edema and tightness in the ankle involving the synovial sheaths of the tendons of muscles in the posterior compartment of the leg
 - The area involved is from the medial malleolus to the calcaneus, and the heel pain results from compression of the tibial nerve by the flexor retinaculum
 - **Hallux Valgus (712)**

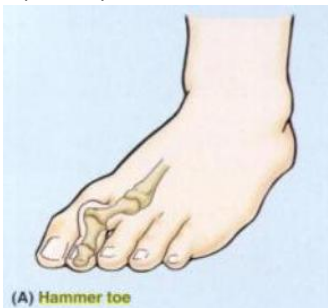
Lower Limb – Jessica Magid

- A foot deformity caused by pressure from footwear and degenerative joint disease
- It is characterized by lateral deviation of the great toe
 - The L in valgus indicates *lateral deviation*
 - In some people, the painful deviation is so large that the great toe overlaps the 2nd toe, and there is a decrease in the medial longitudinal arch
 - Such deviation occurs especially in females, and its frequency increases with age
- These individuals cannot move their 1st digit away from their 2nd digit bc the sesamoids under the head of the 1st metatarsal are usually displaced and lie in the space between the heads of the 1st and 2nd metatarsals
 - The 1st metatarsal shifts medially and the sesamoids shift laterally
- Often the surrounding tissues swell and the resultant pressure and friction against the shoe cause a subcutaneous bursa to form
 - When tender and inflamed, the bursa is called a **bunion**
- Often hard **corns** (inflamed areas of thick skin) also form over the proximal interphalangeal joints, especially the little toe



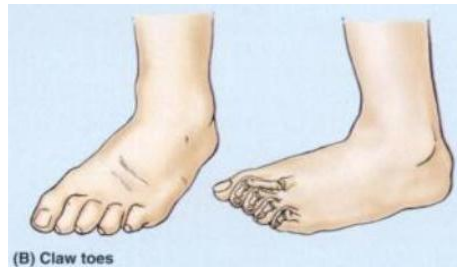- **Hammer Toe (712-713)**

- A foot deformity in which the proximal phalanx is permanently and markedly dorsiflexed (hyperextended) at the metatarsophalangeal joint and the middle phalanx strongly plantarflexed at the proximal interphalangeal joint
 - The distal phalanx of the digit is often also hyperextended
 - This gives the digit (usually the 2nd) a hammer-like appearance
- This deformity of one or more toes may result from weakness of the lumbrical and interosseous muscles, which flex the metatarsophalangeal joints and extend the interphalangeal joints
- A **callosity** or **callus**, hard thickening of the keratin layer of the skin, often develops where the dorsal surface of the toe repeatedly rubs on the shoe



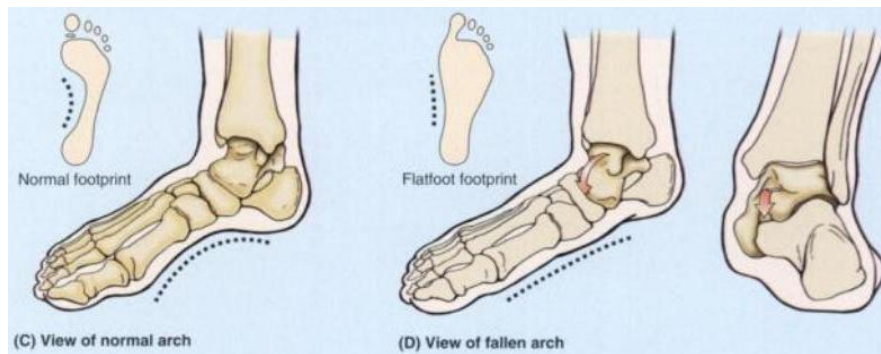
- **Claw Toes (713)**

- Characterized by hyperextension of the metatarsophalangeal joints and flexion of the distal interphalangeal joints
 - Usually, the lateral 4 toes are involved
- Callosities develop on the dorsal surfaces of the toes bc of pressure on the shoe
 - They may also form on the plantar surface of the metatarsal heads and the toe tips bc they bear extra weight when claw toes are present



• **Pes Planus (Flatfeet) (713)**

- The flat appearance of the foot before age 3 is normal and results from the thick subcutaneous fat-pad in the sole
 - As children get older, the fat is lost, and a normal medial longitudinal arch becomes visible
- Flatfeet can be
 - **Flexible** = flat; lacking a medial arch, when weight bearing but normal in appearance when not bearing weight
 - More common
 - Results from loose or degenerated intrinsic ligaments (inadequate passive arch support)
 - Common in childhood but usually resolves with age as the ligaments grow and mature
 - Occasionally persists into adulthood and may or may not be symptomatic
 - **Rigid** = flat even when not bearing weight
 - With a history that goes back to childhood, they are likely to result from a bone deformity, such as a fusion of adjacent tarsal bones
- **Acquired flatfeet** (“fallen arches”) are likely to be secondary to dysfunction of the tibialis posterior (dynamic arch support) owing to trauma, degeneration with age, or denervation
 - In the absence of normal passive or dynamic support, the plantar calcaneonavicular ligament fails to support the head of the talus
 - Consequently, the talar head displaces inferomedially and becomes prominent (red arrow in figure)
 - As a result, some flattening of the medial part of the longitudinal arch occurs, along with lateral deviation of the forefoot
- Flatfeet are common in older people, particularly if they undertake much unaccustomed standing or gain weight rapidly, adding stress on the muscles and increasing strain on the ligaments supporting the arches



• **Clubfoot (Talipes) (714)**

- Refers to a foot that is twisted out of position
 - Of the several types, all are congenital
- **Talipes equinovarus**, the common type (2/100 live births), involves the subtalar joint
 - Boys are affected 2x as often as girls
 - The foot is inverted, the ankle is plantarflexed, and the forefoot is adducted (turned toward the midline in an abnormal manner)
 - The foot assumes the position of a horse’s hoof, hence the prefix “equino”
 - In half of those affected, both feet are malformed
 - A person with an uncorrected clubfoot cannot put the heel and sole flat and must bear the weight on the lateral surface of the forefoot
 - Consequently, walking is painful

Lower Limb – Jessica Magid

- The main abnormality is shortness and tightness of the muscles, tendons, ligaments, and joint capsules on the medial side and posterior aspect of the foot and ankle

